

COMBINAZIONE DI PROTESI CUSTOM-MADE DI BACINO E MEGAPROTESI DI FEMORE PROSSIMALE NEL TRATTAMENTO DELLE GRAVI PERDITE OSSEE DOPO REVISIONI MULTIPLE DI ARTROPLASTICA TOTALE DELL'ANCA



Ortopedia e Traumatologia
IRCCS - Policlinico di S. Orsola

BOLOGNA, ITALY

POLICLINICO DI
SANT'ORSOLA



SERVIZIO SANITARIO REGIONALE
EMILIA-ROMAGNA
Azienda Ospedaliero - Universitaria di Bologna



ALMA MATER STUDIORUM
UNIVERSITÀ DI BOLOGNA

Dr.ssa Azzurra Paolucci
Dr. Renato Zunarelli
Dr. Michele Fiore
Dr. Massimiliano De Paolis

PATROCINI RICHIESTI

ACCADEMIA UNIVERSITARIA DI ORTOPEdia E TRAUMATOLOGIA

Comune di Verona

AIR
ASSOCIAZIONE ITALIANA
RIPROTESIZZAZIONE

IX CONGRESSO NAZIONALE
PRESIDENTE A.I.R. GIUSEPPE SOLARINO

IL RECUPERO DELLE GEOMETRIE ARTICOLARI
NELLE REVISIONI PROTESICHE

VERONA | GRAN GUARDIA | 7-8 MARZO 2024





PRESIDENTE DEL CONGRESSO
CLAUDIO ZORZI

VICEPRESIDENTI
PAOLO AVANZI
ANTONIO CAMPACCI

Segreteria Organizzativa
LGF GROUP
info@lctcongress.com
www.lctcongress.com

Case Report

A Combined Use of Custom-Made Partial Pelvic Replacement and Proximal Femur Megaprosthesis in the Treatment of Severe Bone Loss after Multiple Total Hip Arthroplasty Revisions

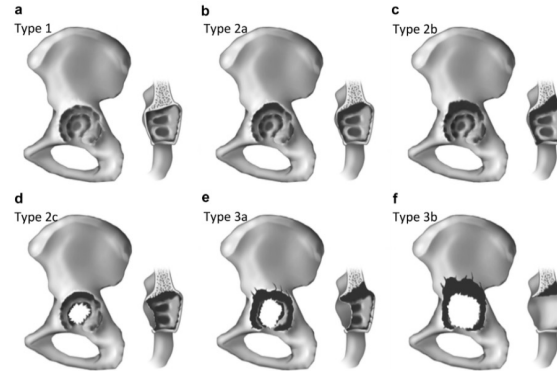
Michele Fiore , Azzurra Paolucci , Renato Zunarelli, Marta Bortoli, Andrea Montanari, Andrea Pace, Lorenzo Di Prinzio, Stefania Claudia Parisi, Roberto De Cristofaro, Massimiliano De Paolis * and Andrea Sambri 

The Known Universe

- Il numero di PTA primarie eseguite aumenta di anno in anno (80mila nel 2021 – RIAP)
- Sempre più PTA vengono eseguite su pazienti sempre più giovani e più attivi
- Il numero di revisioni protesiche (settiche e asettiche) aumenta di anno in anno
- **Il rischio individuale di re-revisione in un paziente che si sottopone a revisione di PTA è del 16% a 3 anni e del 19% a 5 anni**



DIFETTO OSSEO ACETABOLARE



AAOS Classification

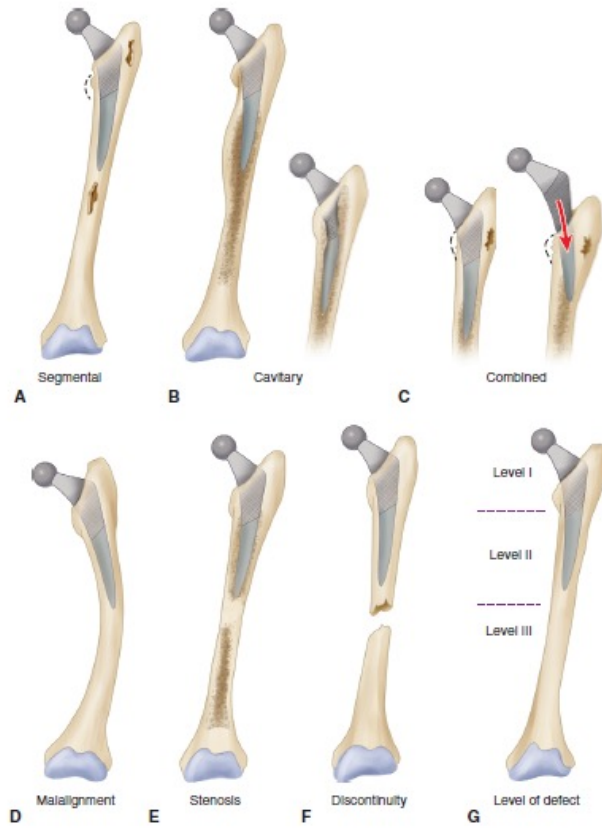
Classification	Description
Type I (segmental)	Loss of part of the acetabular rim or medial wall
Type II (cavitary)	Volumetric loss in the bony substance of the acetabular cavity
Type III (combined deficiency)	Combination of segmental bone loss and cavitary deficiency
Type IV (pelvic discontinuity)	Complete separation between the superior and inferior acetabulum
Type V (arthrodesis)	Arthrodesis

Paprosky Classification

Defect Type	Defect Characteristics
I	Acetabular rim, anterior column, and posterior column intact and supportive; small, local, contained defects
IIA	Moderate superomedial migration <3cm; >50% host-bone contact
IIB	Moderate superolateral migration <3cm; >50% host-bone contact
IIC	Isolated medial migration, medial to Kohler's line; intact rim
IIIA	Severe superolateral migration >3cm; 40-60% host-bone contact; inadequate stability; defect <1/6 circumference
IIIB	Severe superomedial migration; <40% host-bone contact; inadequate stability; medial to Kohler's line; risk of pelvic discontinuity
Pelvic Discontinuity	Partial or complete fracture

DIFETTO OSSEO FEMORALE

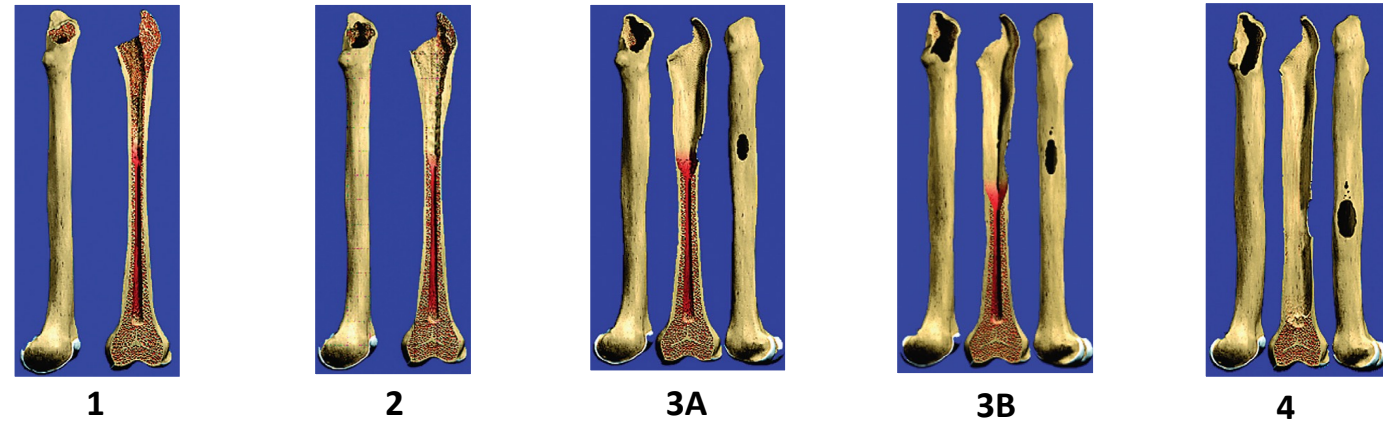
AAOS Classification



Paprosky Classification

Paprosky Classification for STEM

	bone loss	Implant Choice
Type 1	minimal metaphyseal	primary stem for metaphyseal ingrowth (if concern for rotational stability, use fully coated implant for diaphyseal ingrowth)
Type 2	extensive metaphyseal, no diaphyseal loss	fully porous coated stem for diaphyseal ingrowth, or S-ROM type
Type 3	extensive metaphyseal & diaphyseal	
3A	> 4 cm intact bone proximal to isthmus	fully porous coated stem for diaphyseal ingrowth, either monoblock or modular stem
3B	< 4 cm ""	modular stem
Type 4	unsupportive diaphysis (beyond isthmus)	cannot obtain initial press-fit for bony ingrowth. Total femoral replacement versus Allograft Prosthetic Composite



PROTESI PELVICA CUSTOM-MADE

INDICAZIONI:

- Ricostruzioni oncologiche
- Revisioni protesiche
- Traumatologia
- Deformità

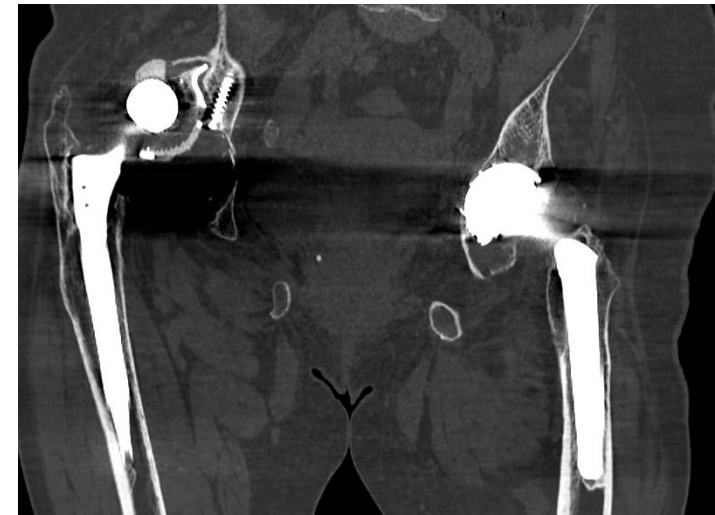
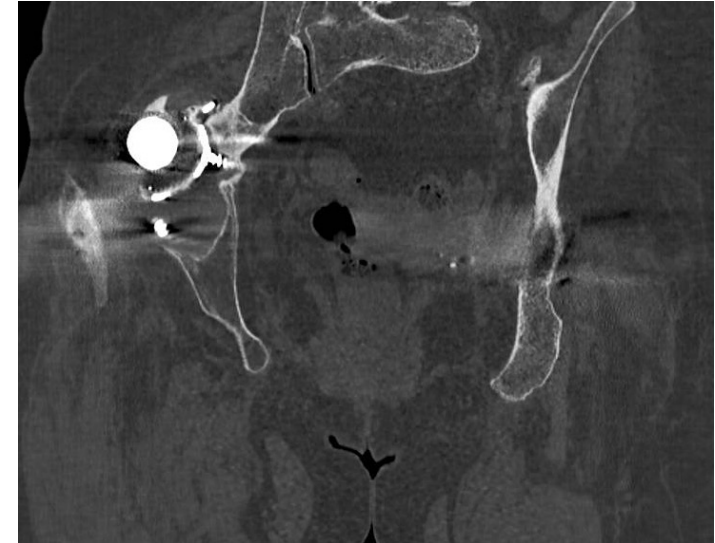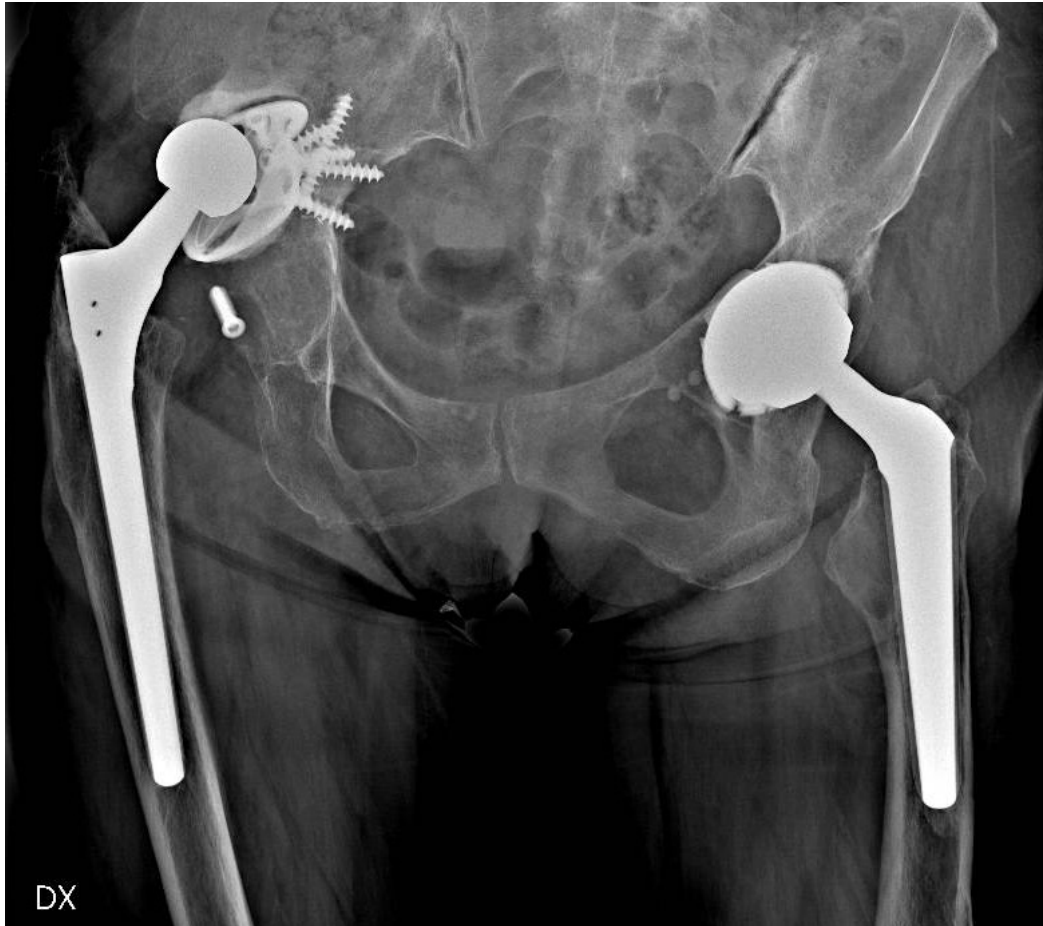VANTAGGI:

- Ricostruzioni anatomiche
- Indicata per i difetti ossei massivi
- Riduzione del tempo chirurgico
- Paziente-specifica

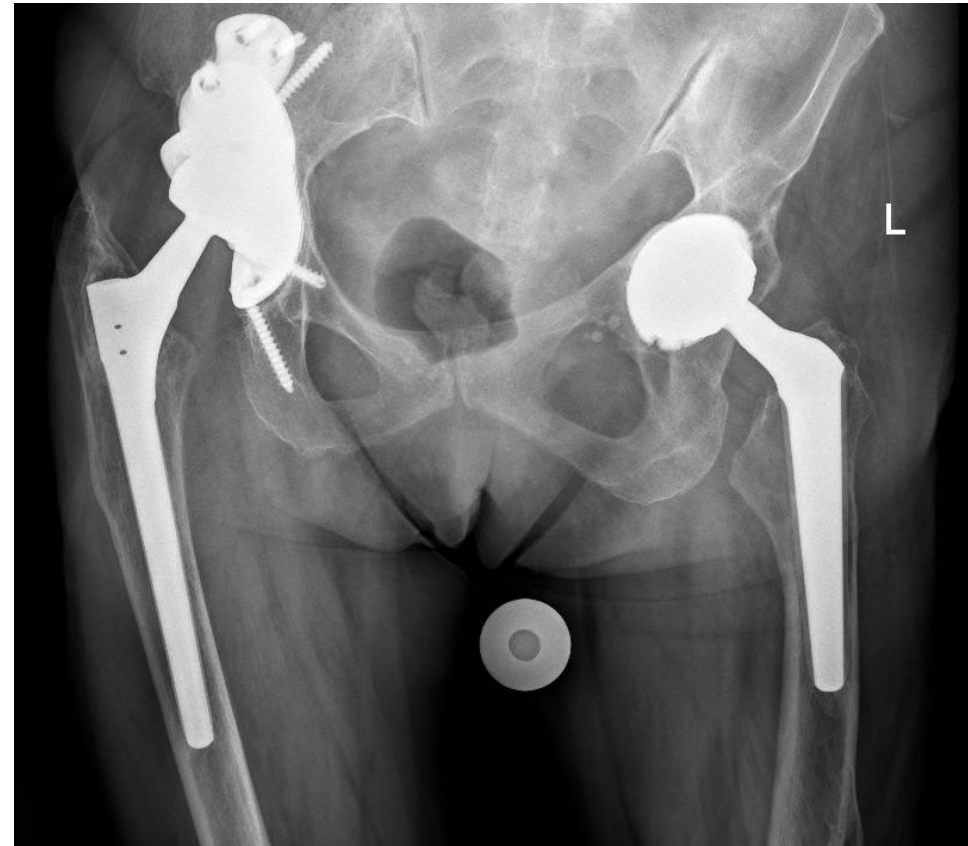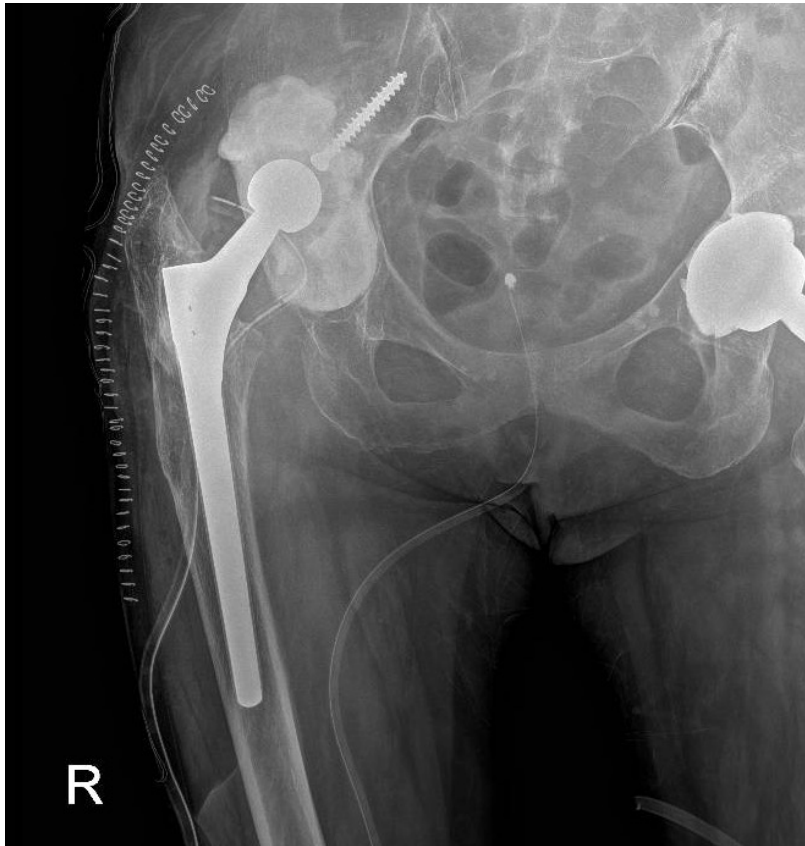SVANTAGGI:

- Costi elevati
- Tempo necessario alla produzione
- Difficoltà della tecnica chirurgica


CASO CLINICO: C.L., 68 ANNI



FOLLOW-UP 24 MESI

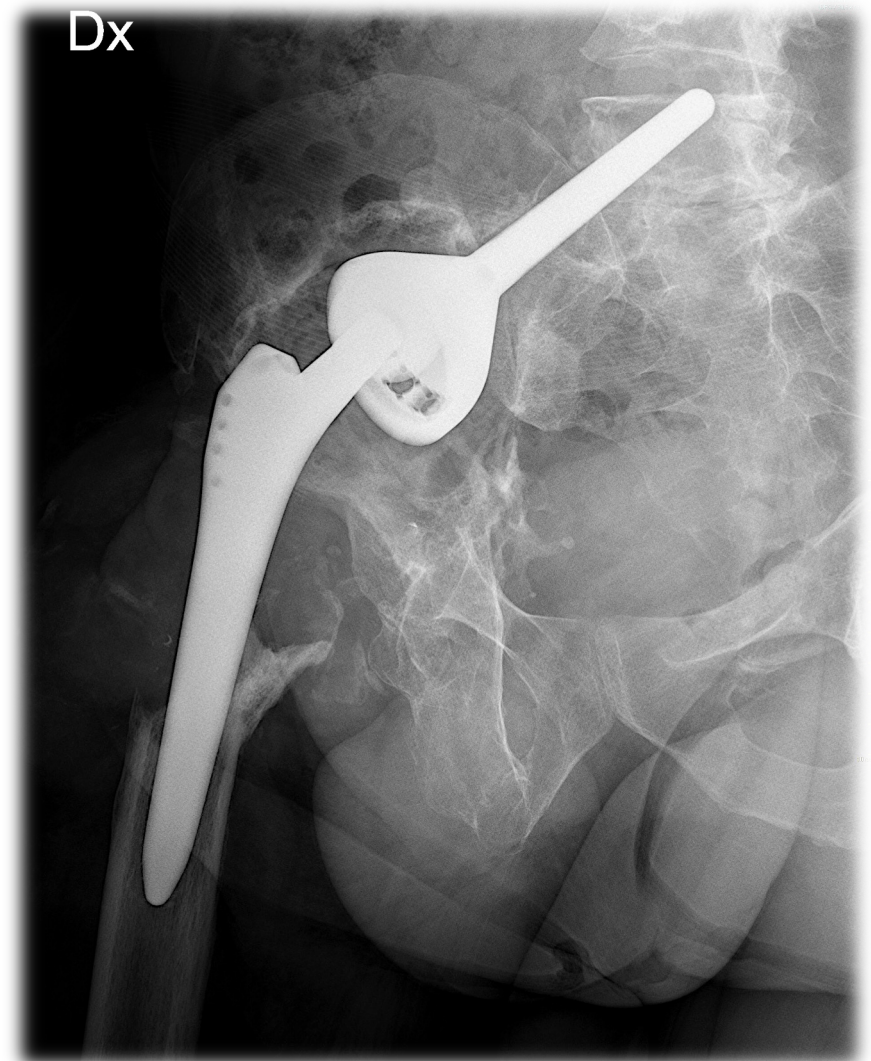
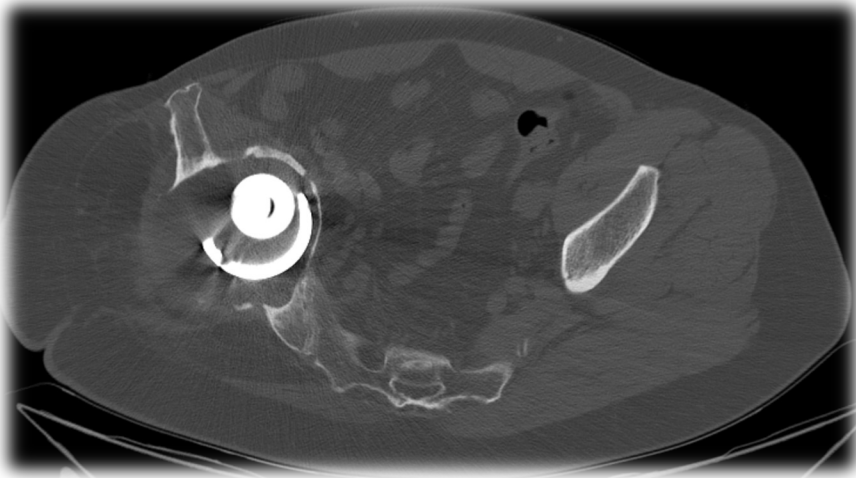


MANCATO RIPRISTINO DI UN BUON CENTRO DI ROTAZIONE

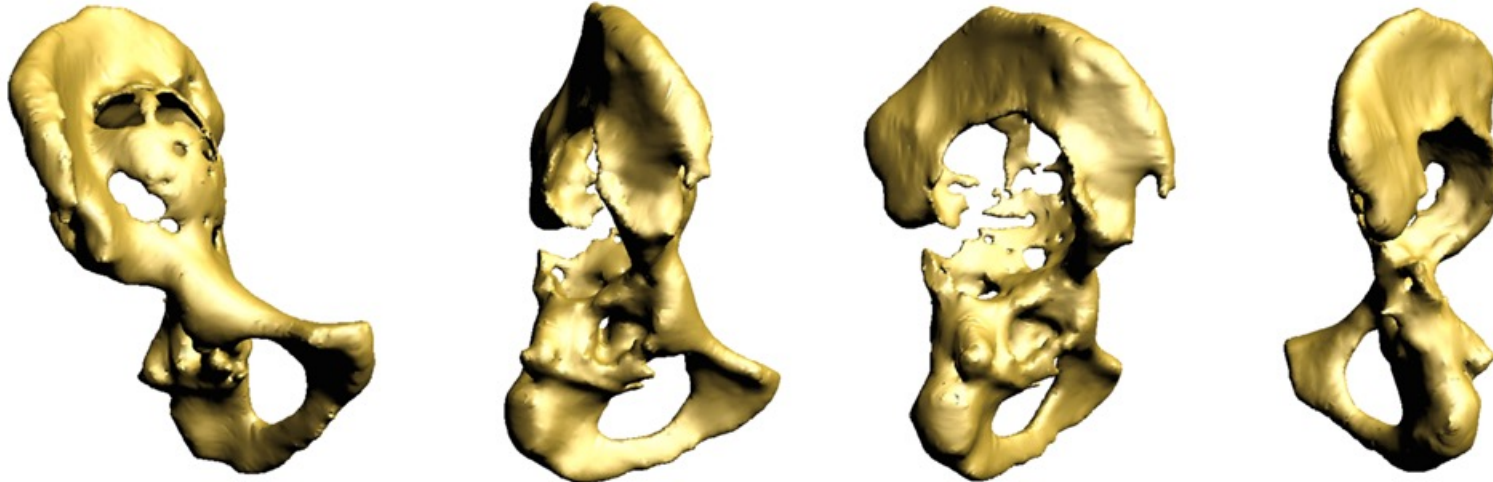


CASO CLINICO: G.P., 49 ANNI

- Frattura dell'acetabolo e del femore prossimale 28 anni prima
- 7 pregressi interventi, 1 Two-stages per PJI
- PTA da revisione con cotile a stelo iliaco
- **Mobilizzazione** dell'impianto con migrazione in cavità pelvica
- Severo **difetto osseo** acetabolare e femorale
- **Ipometria** 4 cm
- **Pseudotumor** con metallosi



DIFETTO OSSEO



Come gestirlo?



Cotile/anelli da revisione

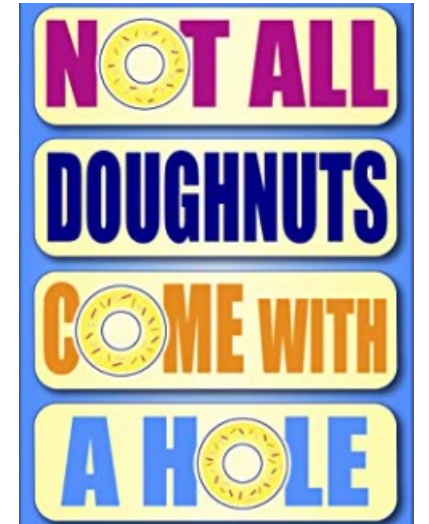


Protesi custom made

PROTESI CUSTOM-MADE

- **Resezione (Resection custom)**
 - Principalmente nei casi oncologici
 - Minor quantità e qualità di osso residuo

- **Riempimento (filling custom)**
 - Principalmente nei casi non oncologici
 - Osso sano intorno al difetto



REVISIONE ONE STAGE O TWO-STAGES ?

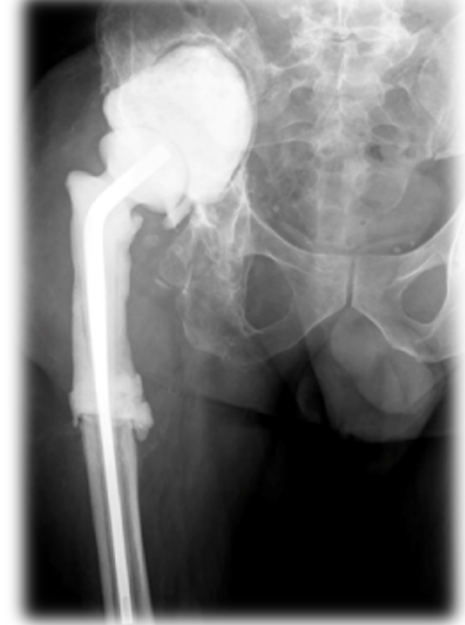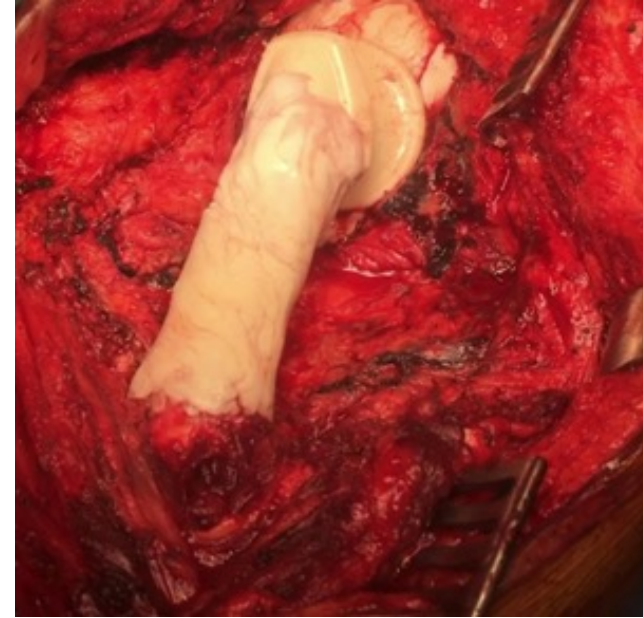
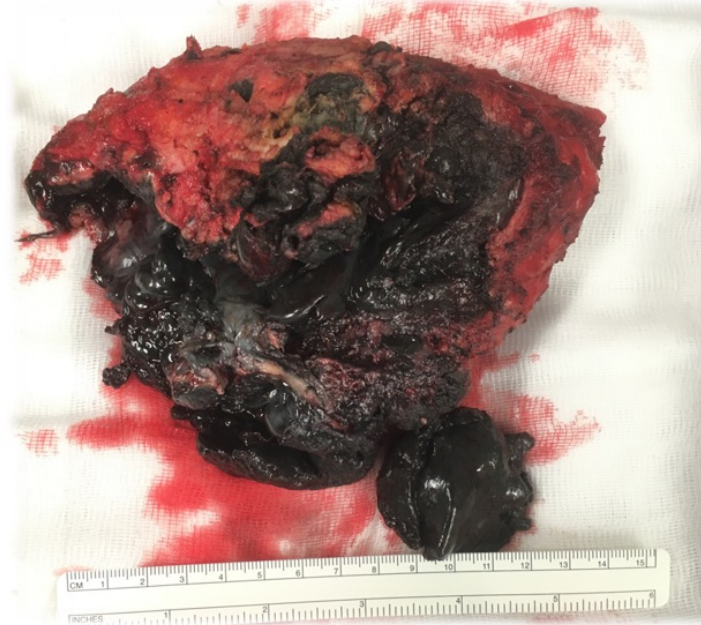
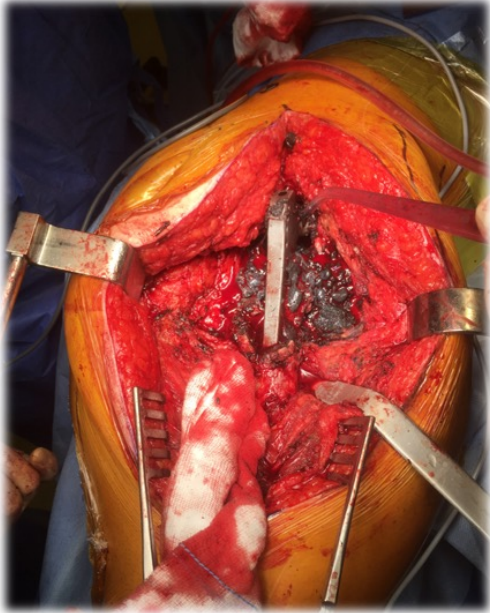
TWO-STAGES !

- Rule-out infettivologico
- Miglior qualità del planning pre-operatorio
- Pseudotumor

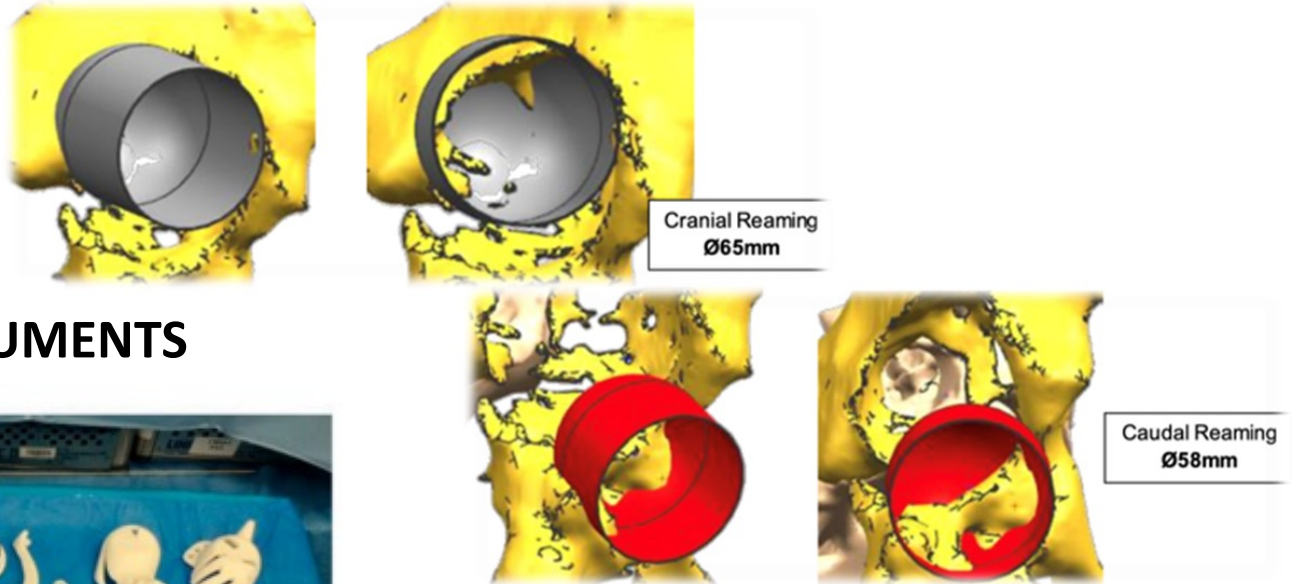
FIRST THINGS FIRST



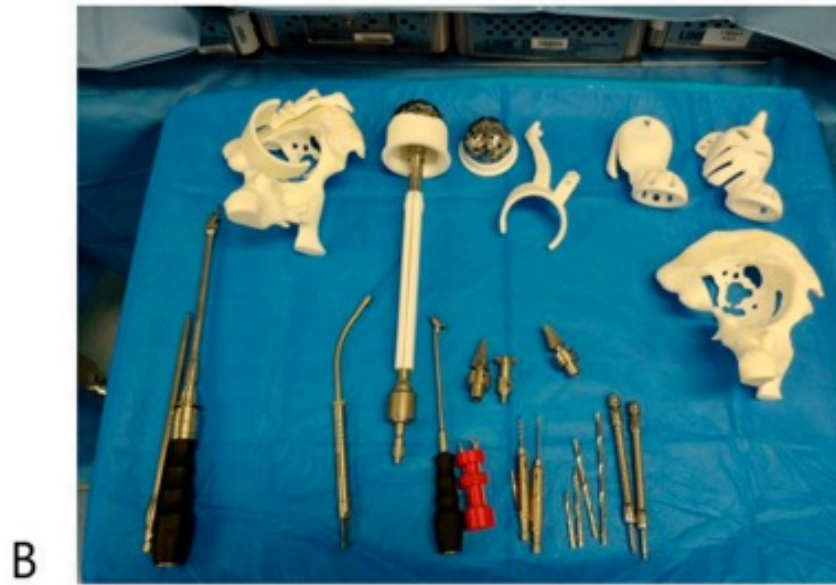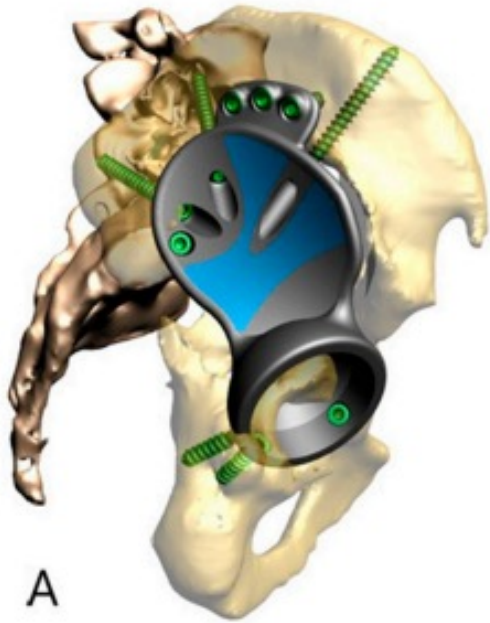
PRIMA FASE: ESPIANTO E POSIZIONAMENTO SPAZIATORE






REAMING GUIDES



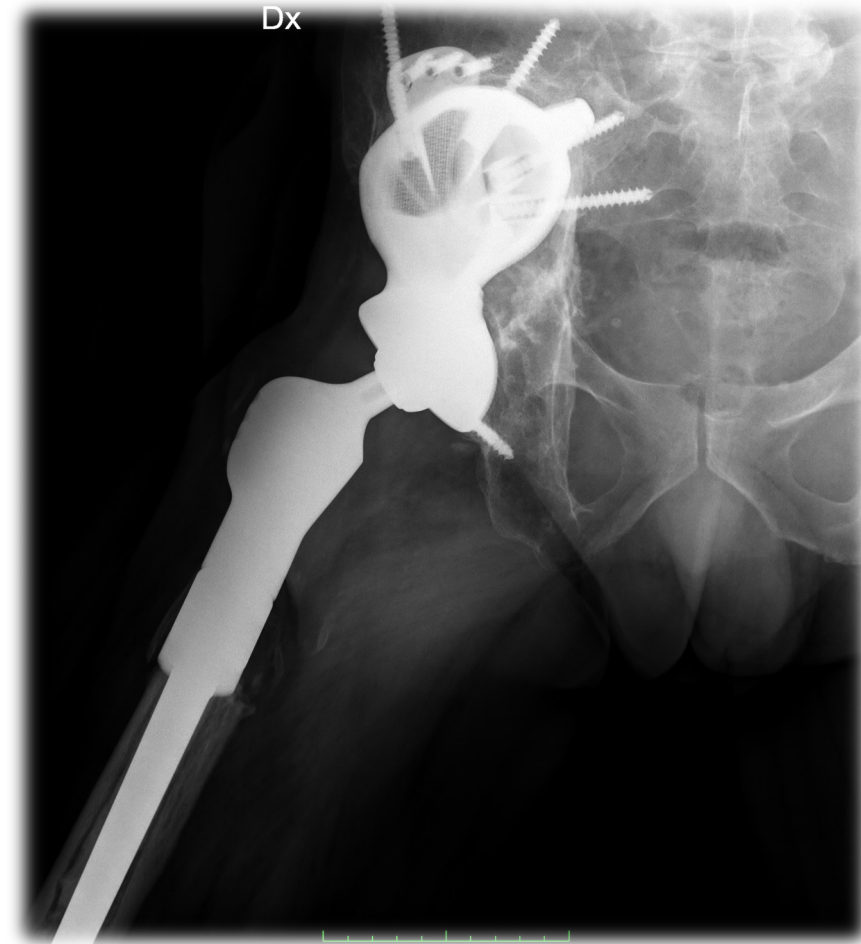
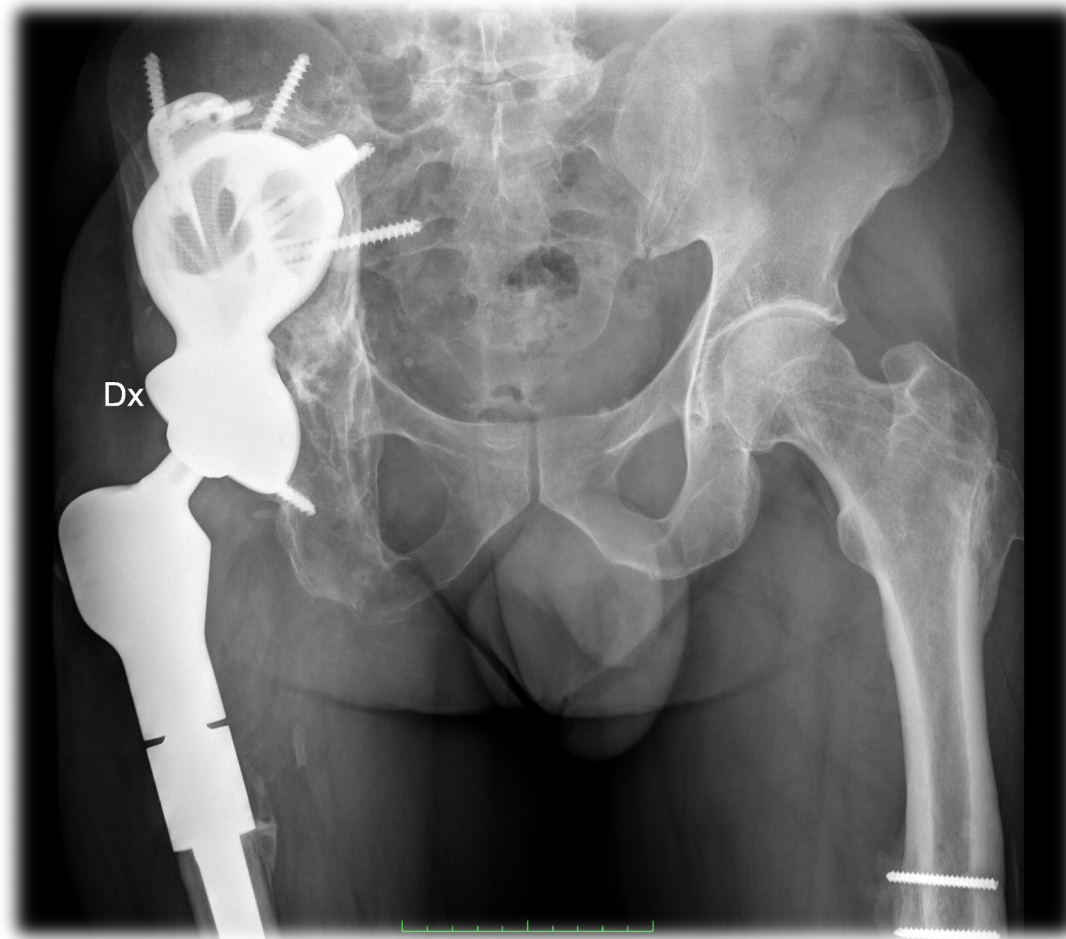
PROTESI CUSTOM E PATIENT-SPECIFIC INSTRUMENTS

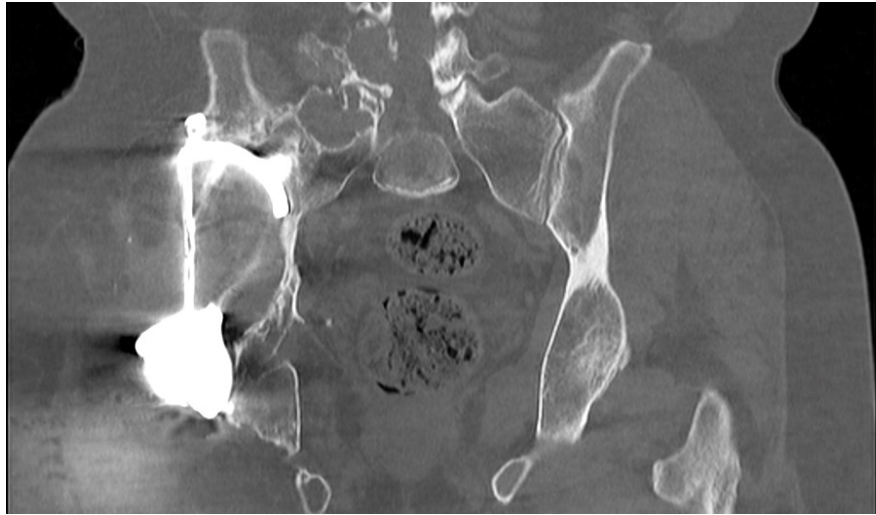




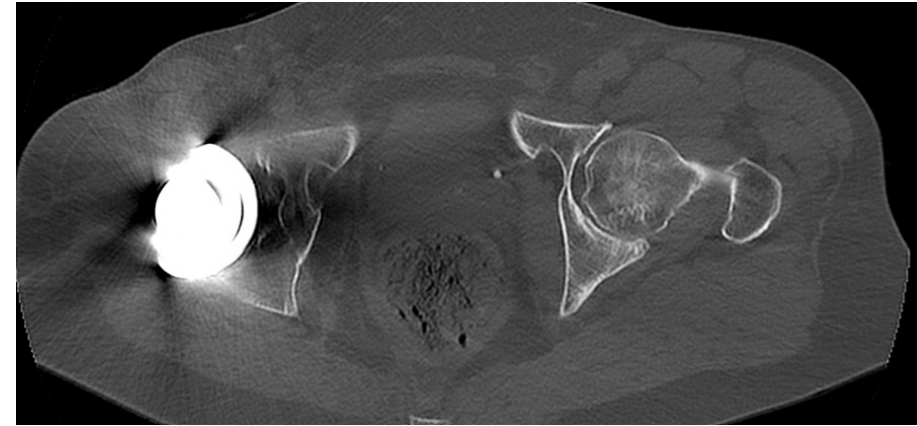


FOLLOW-UP 24 MESI

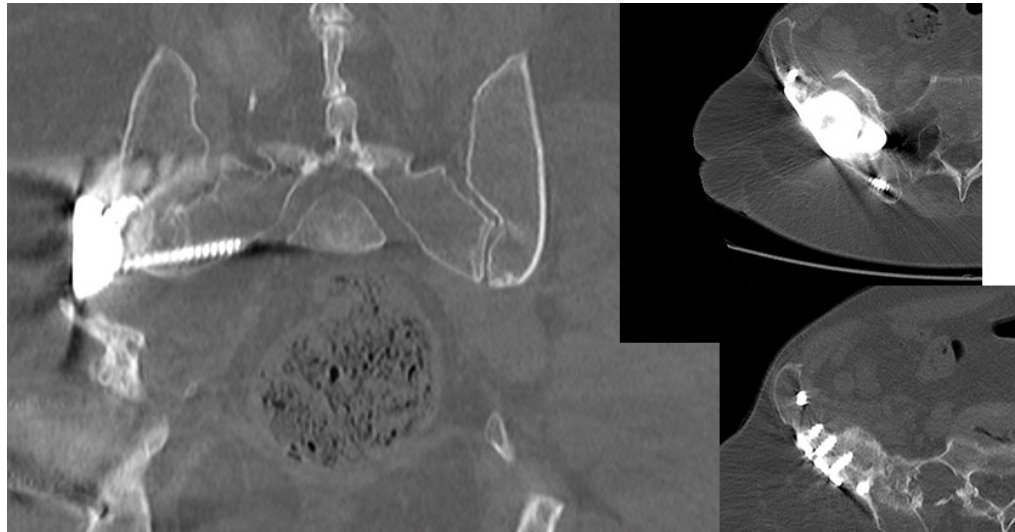




Contatto osso-
impianto ✓



Posizionamento
cotile ✓




Posizionamento viti



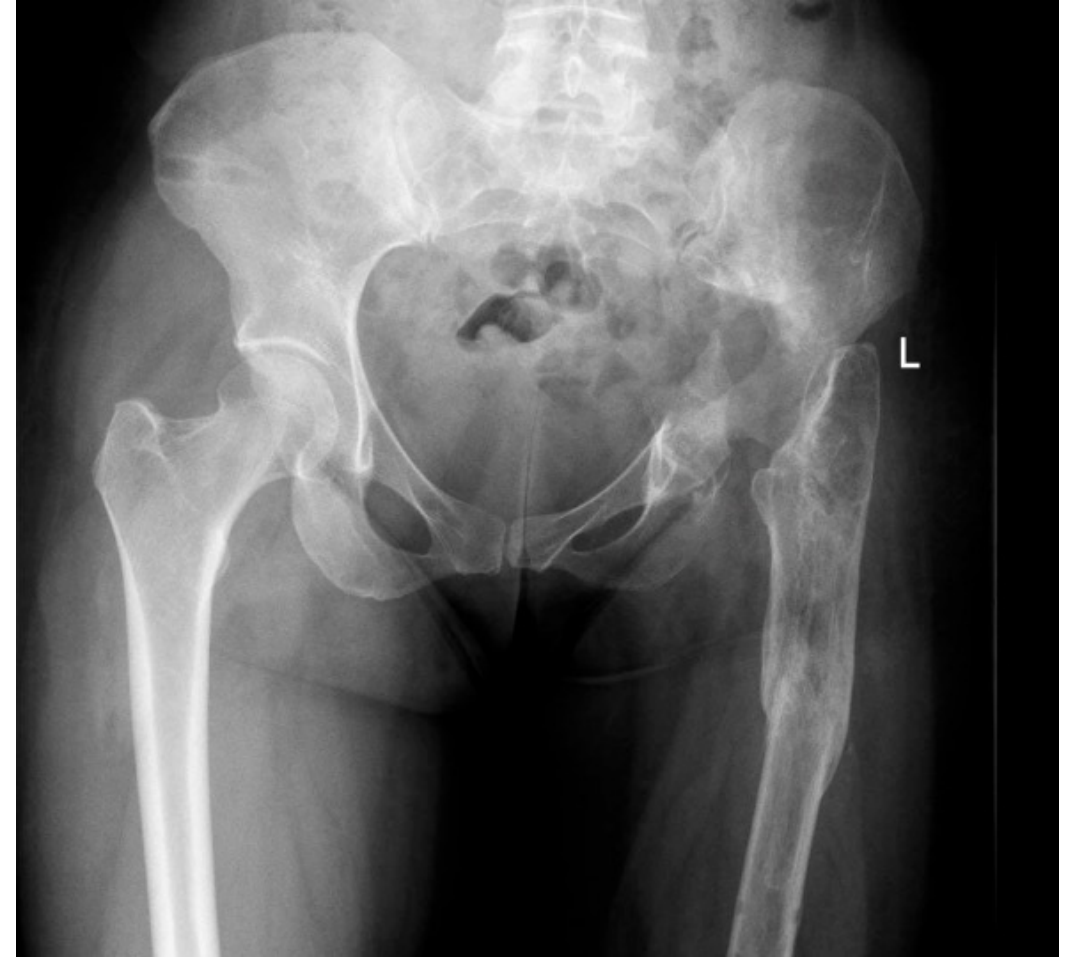OTTIMO RIPRISTINO DEL CENTRO DI ROTAZIONE





CASO CLINICO: G.L., 37 ANNI

- PTA sin a 17 anni
- Multiple revisioni protesiche con in **PJI** PTA sinistra 10 mesi prima trattata con protocollo Two-stages con Girdlestone, espianto complicato da frattura intra-operatoria
- Severo **difetto osseo acetabolare e pseudoartrosi femore prossimale**
- **Ipometria** sinistra di 4.5 cm



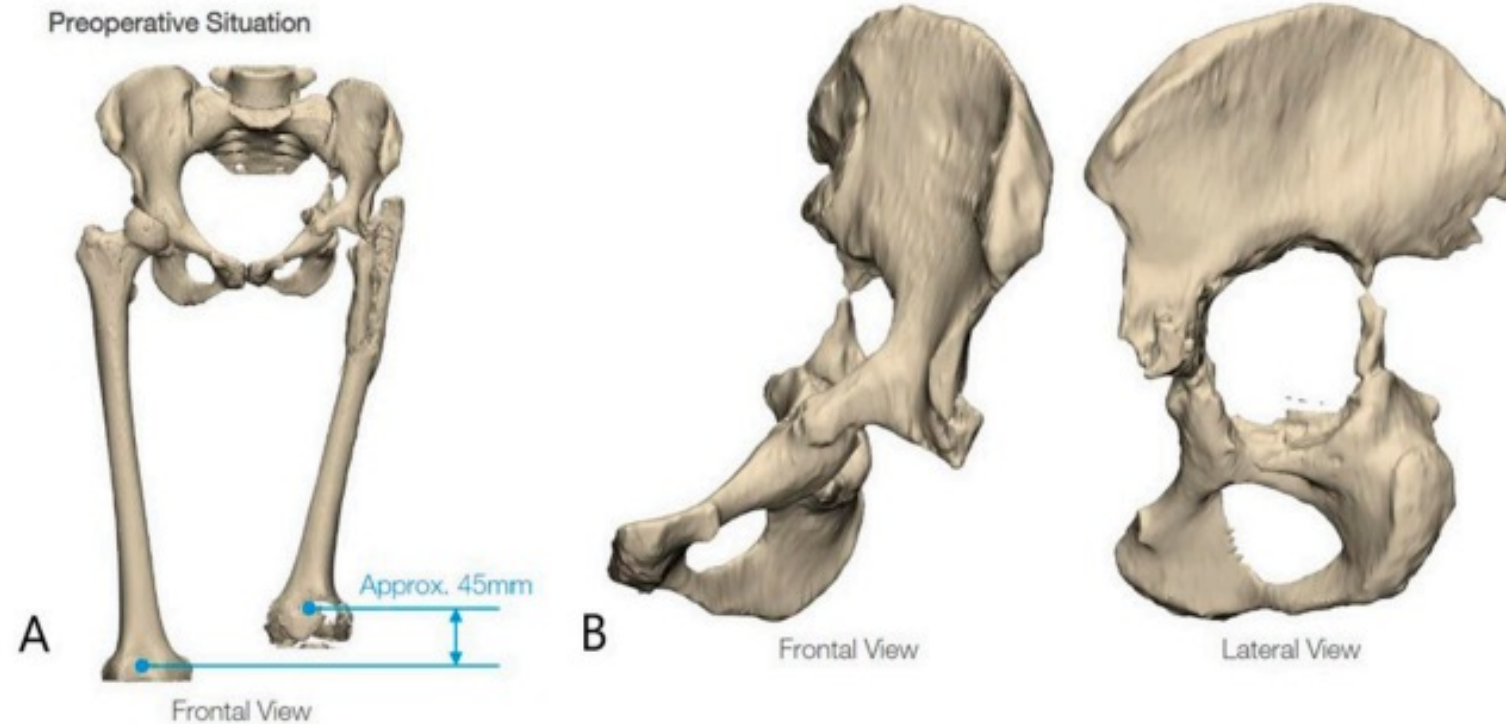
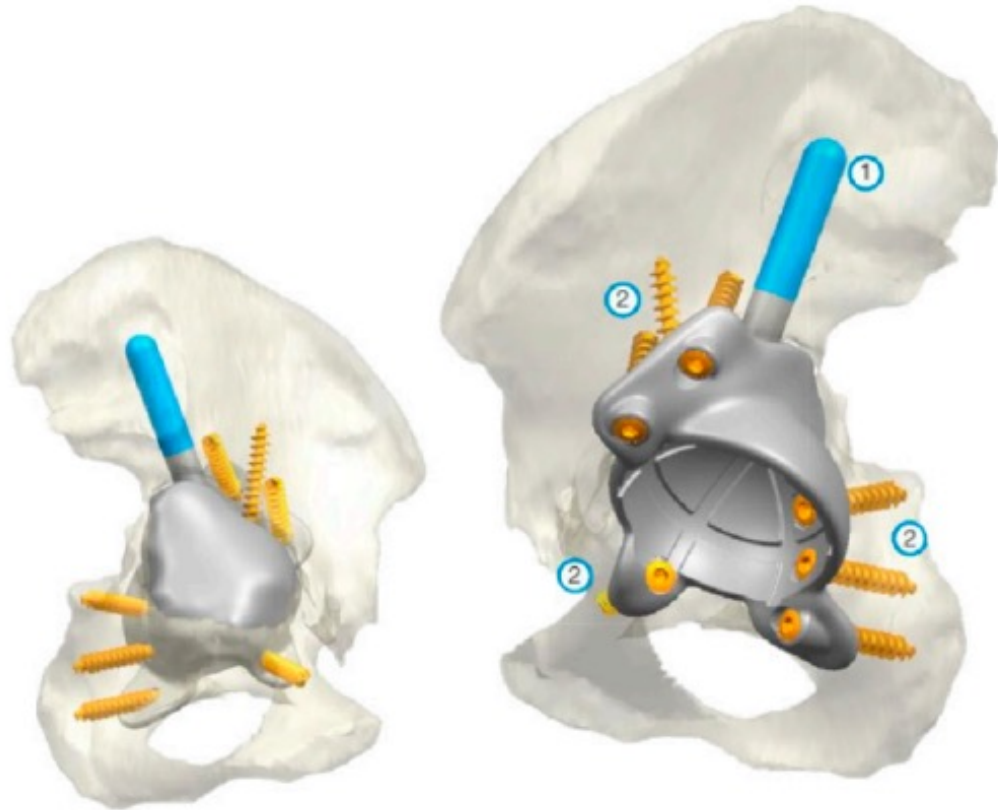


Figure 6. Three-dimensional reconstruction of the pelvis and proximal femur based on computerized tomography scans. (A) highlights a length discrepancy of approximately 45 mm. (B) Type 3C Paprosky acetabular bone defect.



Femoral Planning – PorAg coated

Stem Components



Note:
After positioning the support ring,
the set screw must be fixed!

Stem Segments, Ø 28 mm

REF	Length (L)
15-8522/02	30 mm
15-8522/04	50 mm
15-8522/06	50 mm
15-8522/08	60 mm
15-8522/10	100 mm
15-8522/12	150 mm
15-8522/14	200 mm
15-8522/16	250 mm

Support Rings, height (H) 10 mm


REF	For stem Ø	Height (H)
15-8502/66	up to Ø 18 mm	10 mm

Neck Segments, massive, MEGASYSTEM-C

REF	Length	CCD angle
15-8503/35	65 mm	135°
15-8503/28	65 mm	126°
15-8504/35	35 mm	135°
15-8504/28	35 mm	126°



Coupling Components for total femur (A) and proximal femur replacement (B)

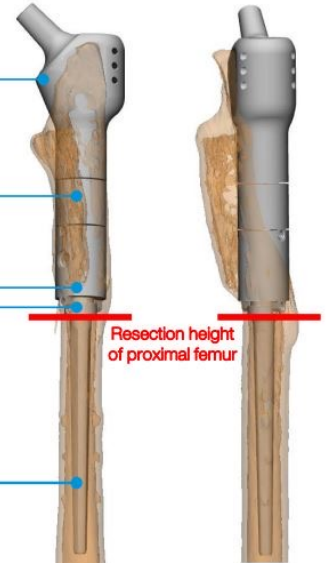
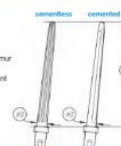


REF	For replacement:	Height (H)
15-8522/24	Total femur replacement (A) short	20 mm
15-8522/26	Total femur replacement (A) long	20 mm
15-8522/28	Proximal femur replacement (B) short	30 mm
15-8522/30	Proximal femur replacement (B) long	30 mm

Modular Stems* with dual taper (for 6 mm flanges)

REF	Stem length L	Cemented	
		REF	Stem length L
15-8524/40	Ø 13/9 mm	15-8523/48	Ø 12/8 mm
15-8524/42	Ø 14/11 mm	15-8523/42	Ø 14/10 mm
15-8524/44	Ø 16/13 mm	15-8523/44	Ø 16/12 mm
		15-8522/44	Ø 16/11 mm

- * These modular stems can be combined with:
 - Coupling device to assemble a proximal partial femur replacement
 - Femoral joint component, solid, or a stem segment attached to it to assemble a distal partial femur replacement
 - Coupling device for the diaphyseal spacer
 - Proximal tibial replacement

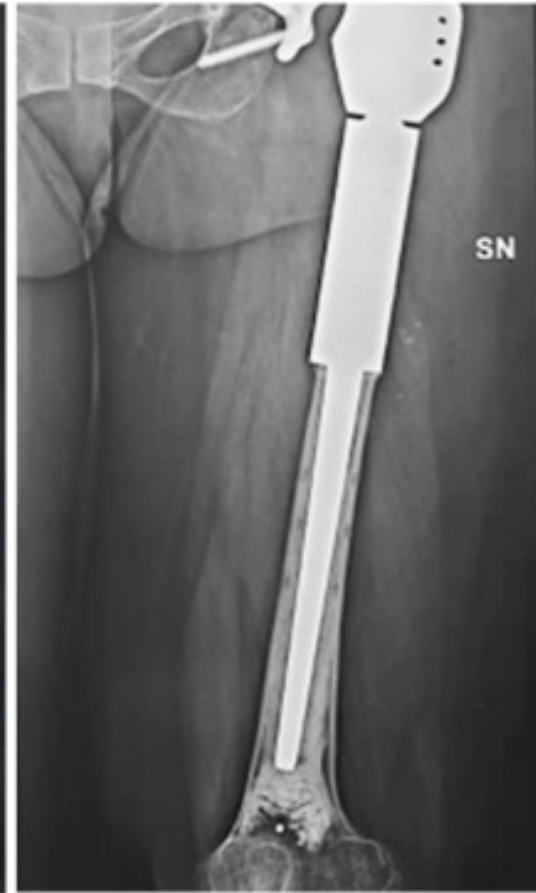
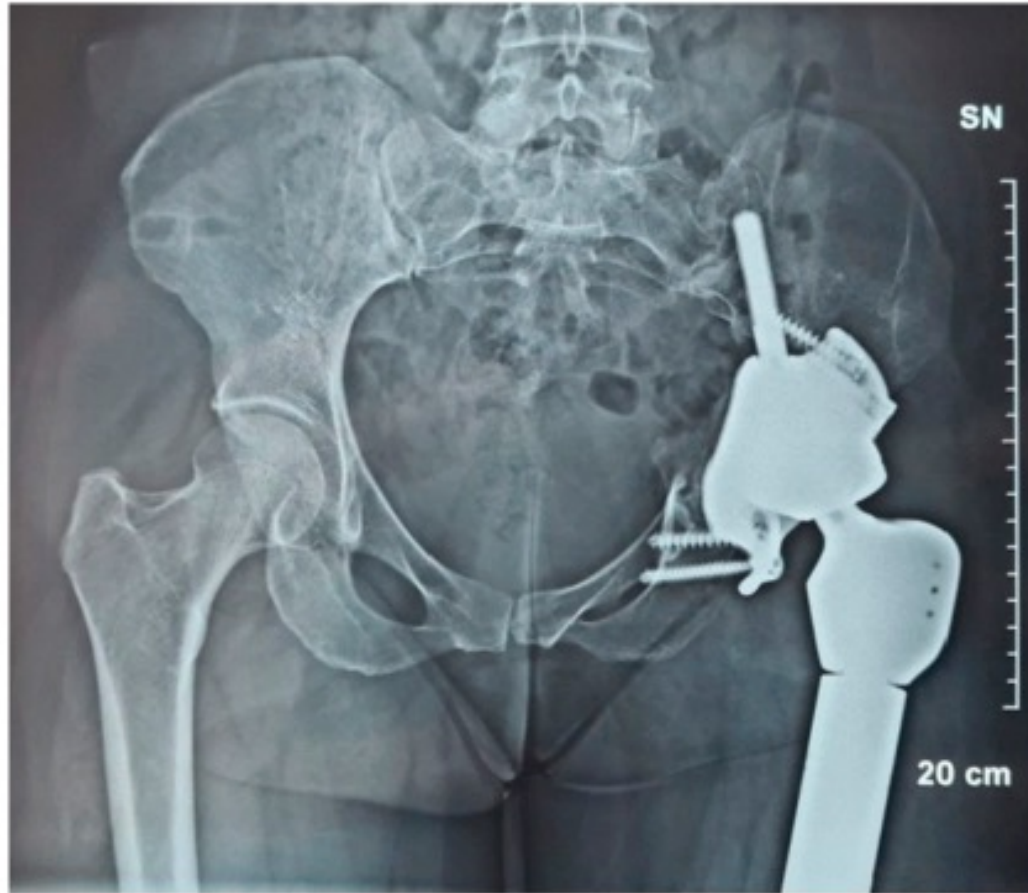


Equalized leg lengths with proposed components of femoral replacement (see also page 4)

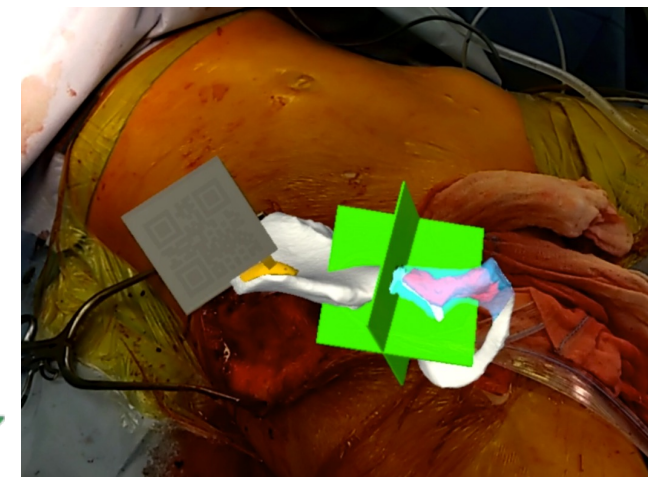

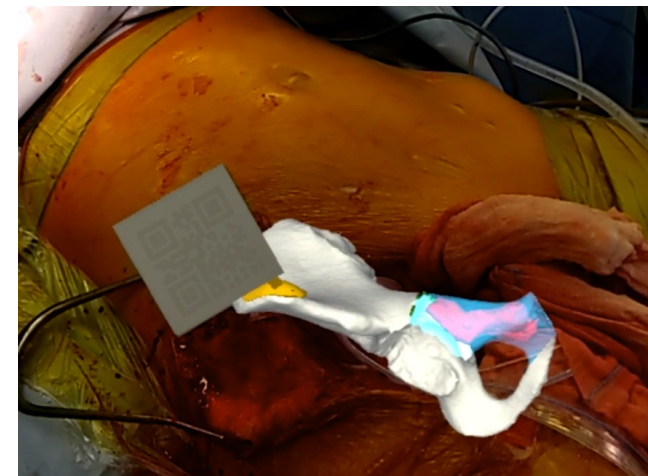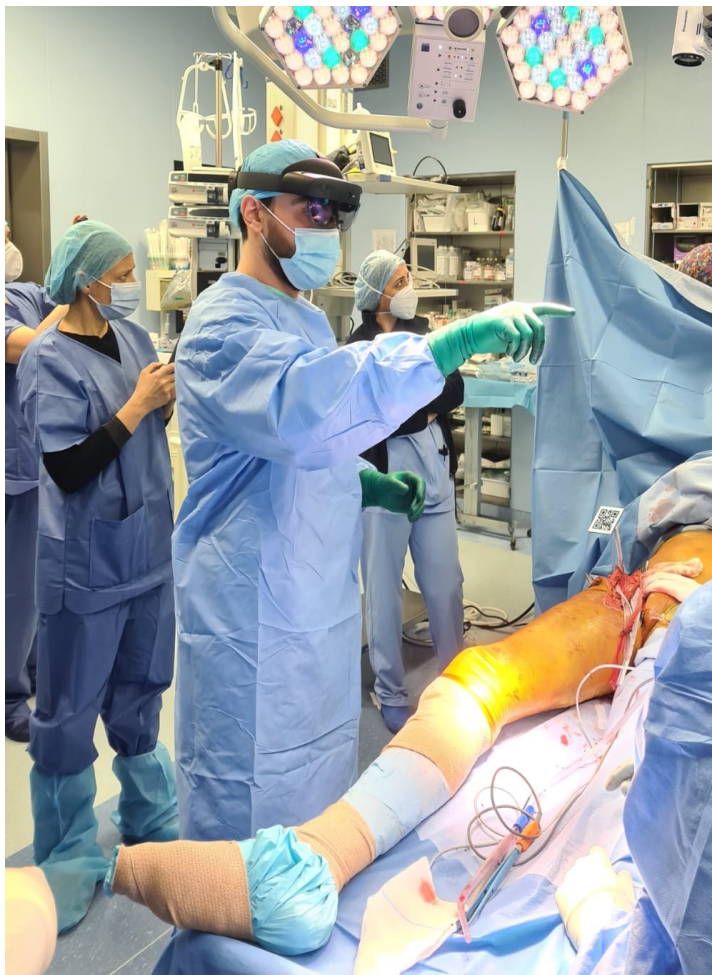
Delivery scope:

- Short and Long Neck Segment, 126°;
- Short and Long Coupling Component for Proximal Femur;
- 41mm and 61mm Expansion Bolt;
- 30mm and 40mm Stem Segment;
- Support Ring;

FOLLOW-UP 24 MESI

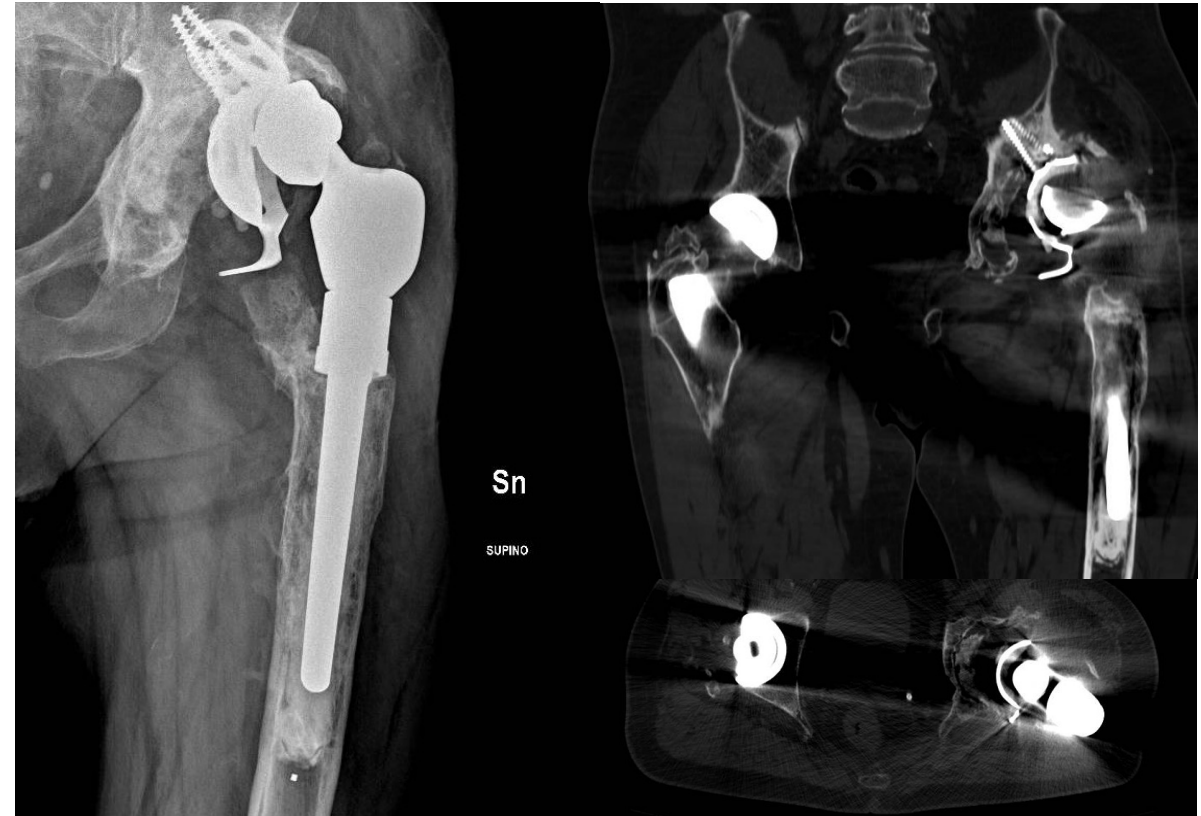

REALTA' AUMENTATA



CASO CLINICO: P.L., 68 ANNI

- Protesi di rivestimento anca sinistra a 50aa
- Multiple revisioni protesiche
- **PJI** sinistra nel 2020 trattata con protocollo Two-Stages (Girdlestone) e successivo reimpianto di Anello di Burch-Schneider + Megaprotesi FP
- **Mobilizzazione** asettica Anello di Burch-Sneider
- **Grave difetto osseo acetabolare e femorale**



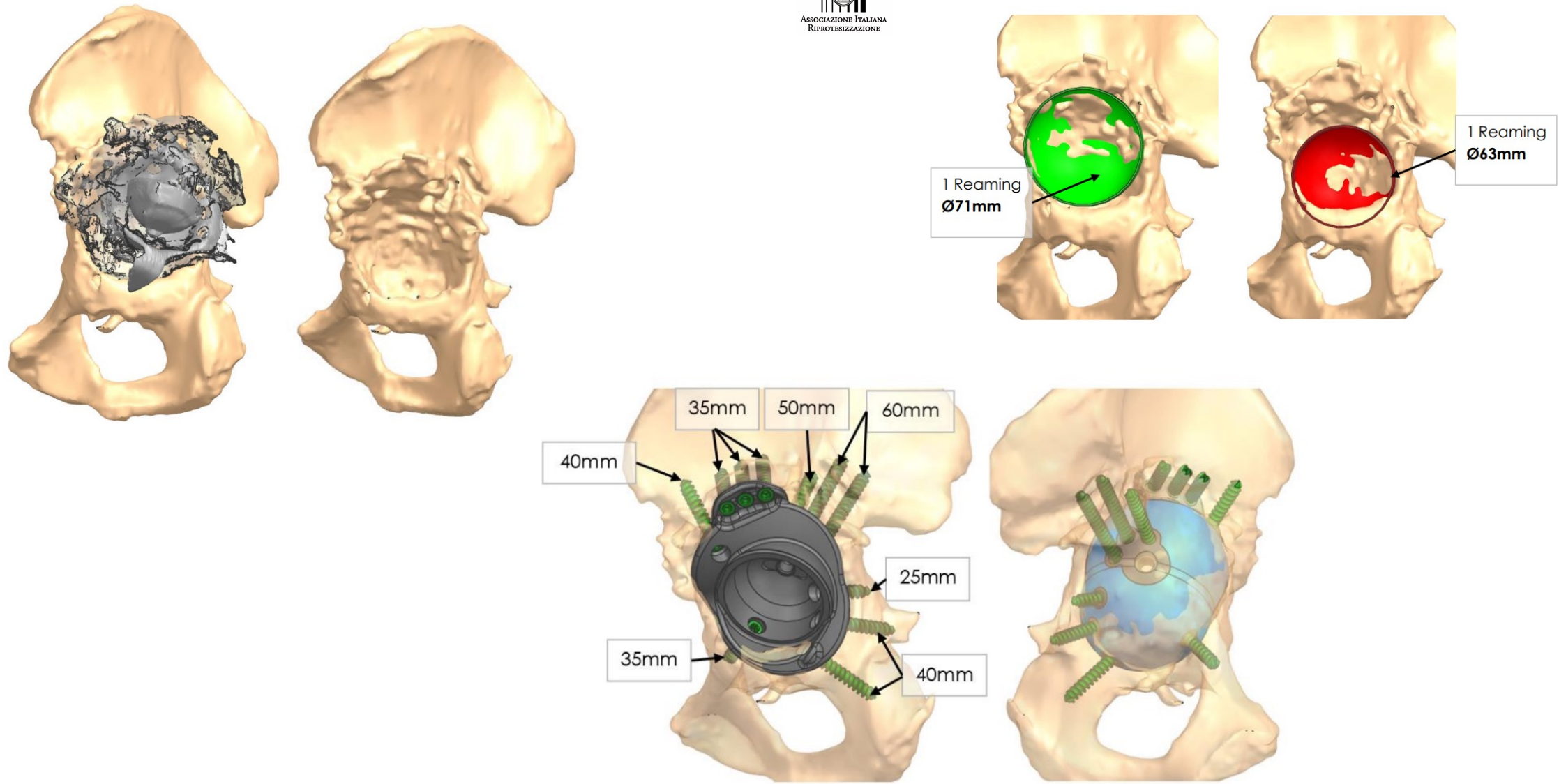
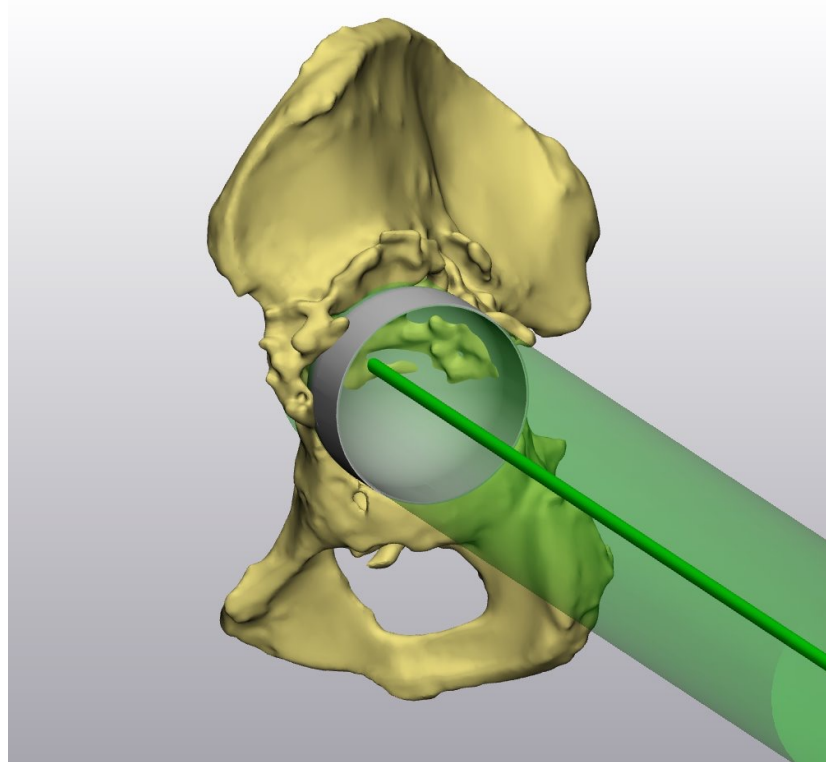
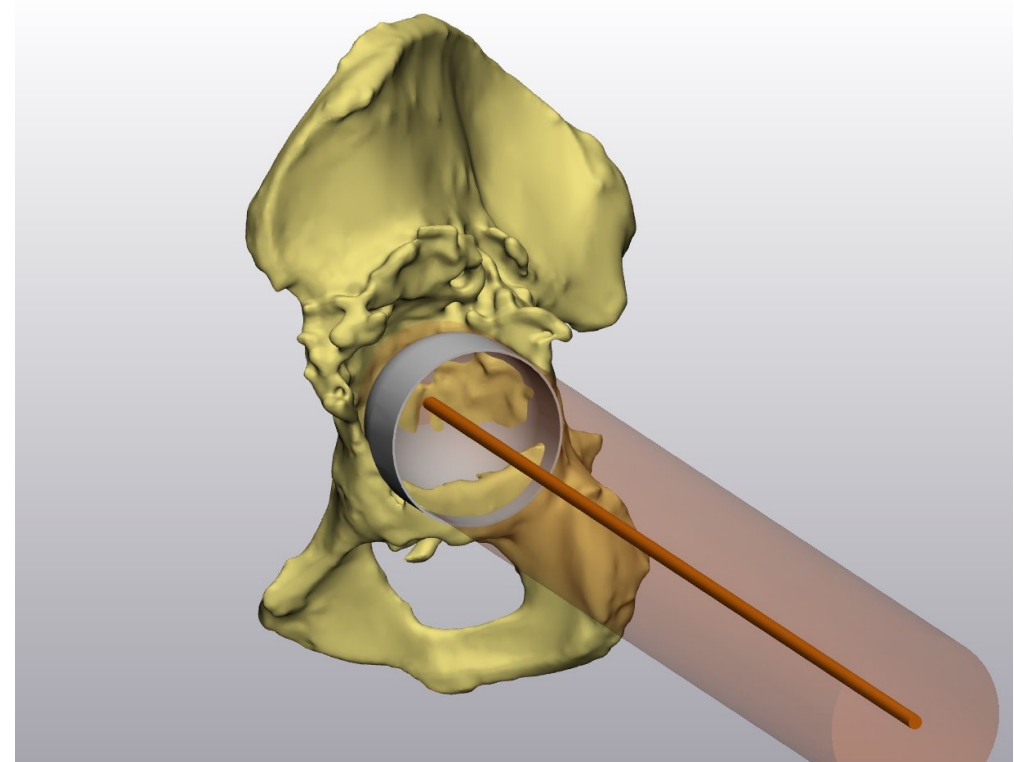


Fig. 5: Implant position and fixation

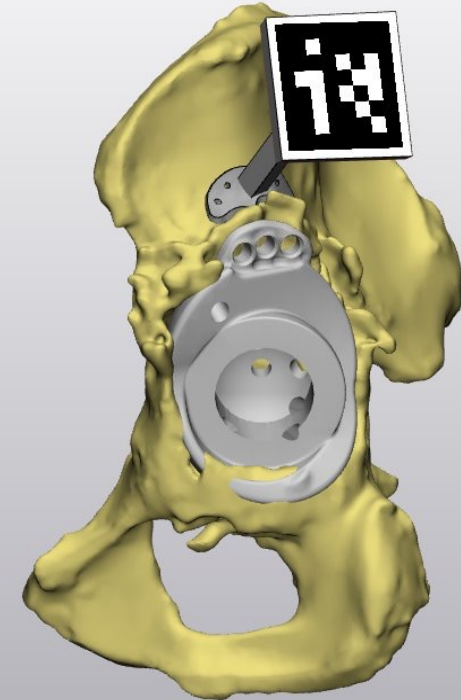
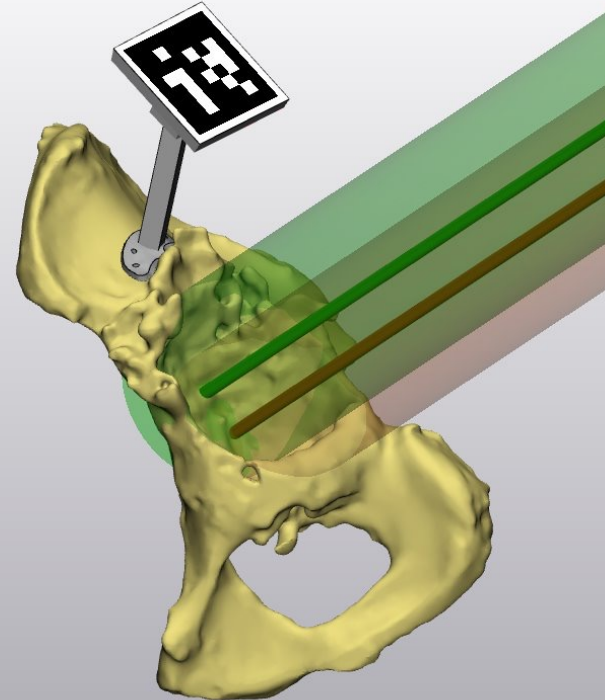
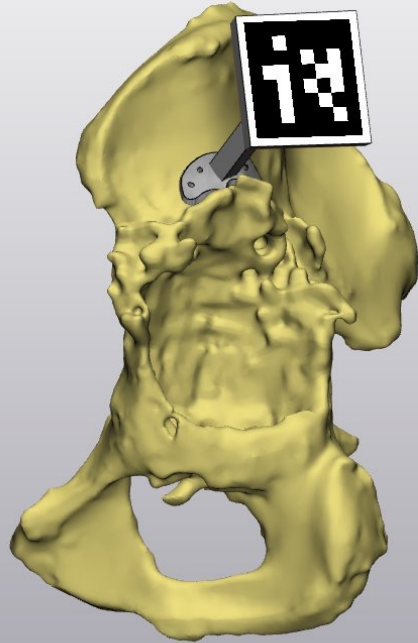
CRANIAL REAMING




CAUDAL REAMING

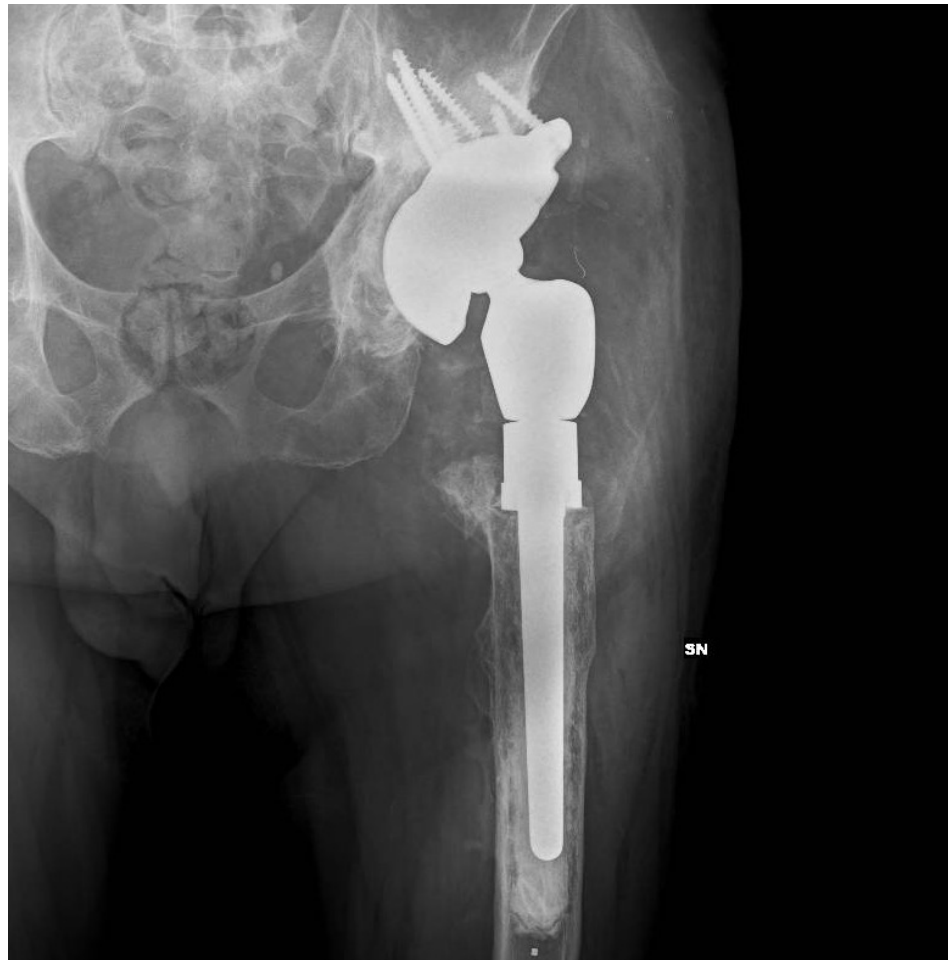

POSIZIONAMENTO TRACKER E REALTA' AUMENTATA

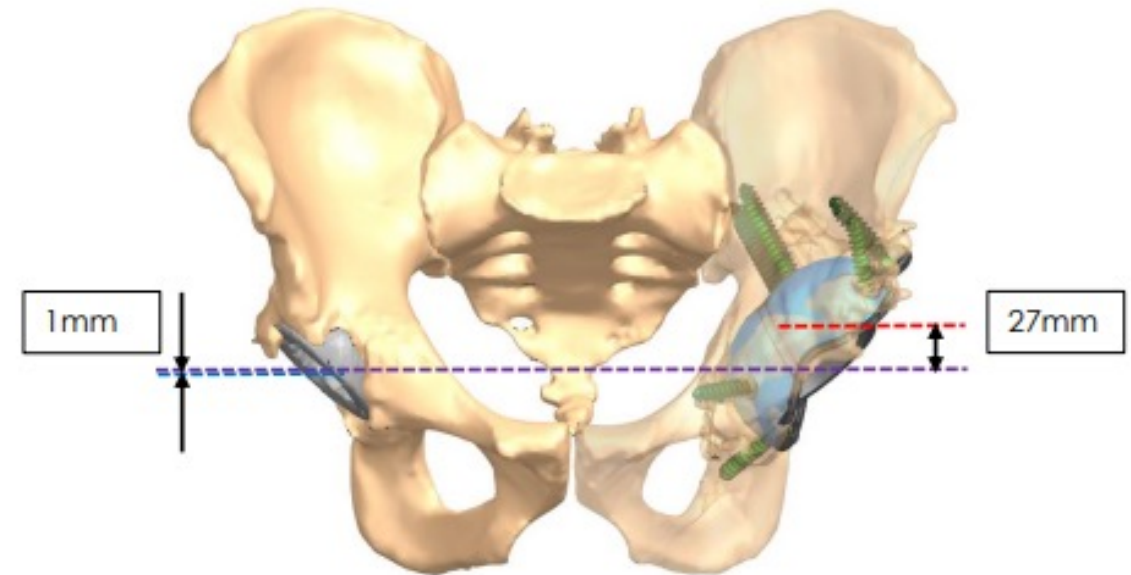




FOLLOW-UP 6 MESI



- **Positioning:** Centre Of Rotation recovery (COR); Leg length recovery (27mm)



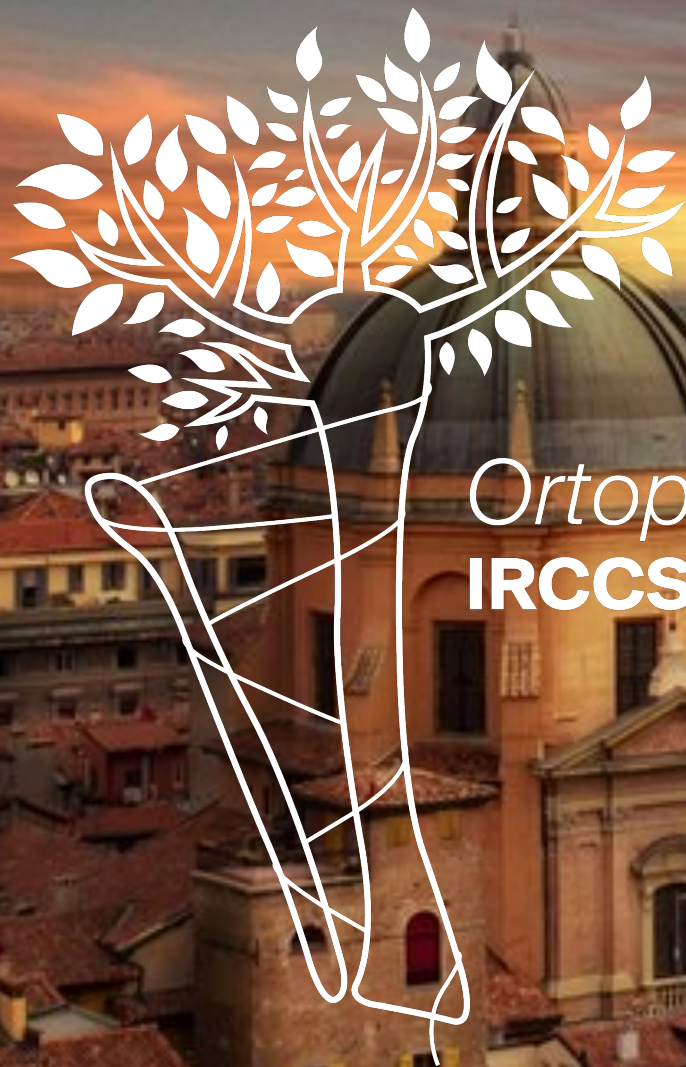TAKE HOME MESSAGES

Impianti custom-made come valido approccio ai gravi difetti ossei

Nei grandi difetti ossei considerare la combinazione di protesi custom di bacino + megaprotesi di femore prossimale per il ripristino del centro di rotazione e della lunghezza

Il planning pre-operatorio è il cardine del successo nella customizzazione

La Realtà Aumentata ottimizza il planning, rappresenta un valore aggiunto alle reaming guides, aumenta la consapevolezza dell'operatore



Ortopedia e Traumatologia
IRCCS - Policlinico di S. Orsola